

Three Dimensional Volumetric Analysis of the Maxillary Sinus Using Computed Tomography from Usmanu Danfodiyo University Teaching Hospital, Sokoto, Nigeria

*¹Abdulhameed A., ¹Zagga A. D., ²Ma'aji S. M., ¹Bello A., ¹Bello S. S.,
¹Usman J. D., ¹Awwal M. M. and ¹Tadros A. A.

¹Department of Anatomy, College of Health Sciences,
Usmanu Danfodiyo University, Sokoto, Nigeria

²Department of Radiology, Usmanu Danfodiyo University Teaching Hospital, Sokoto
*E-mail: anastomosis74@gmail.com, aliuabdulhameed@yahoo.com.

ABSTRACT

The maxillary sinus is a pneumatic cavity within the maxilla. The extent of pneumatisation varies among individuals; its volume is influenced by age, and alveolar bone height, prompt evaluation of the maxillary sinus volume is useful in sinus surgery. The aim of this study is to determine volume of the maxillary sinus using computed tomography, to correlate this with side, age and sex and to provide baseline data for values in our environment. A retrospective evaluation of 130 subjects (79 males and 51 females), between 20 - 80 years, with normal maxillary sinus CT anatomy, from head CT scans was carried out at the Radiology Department of the Usmanu Danfodiyo University Teaching Hospital, Sokoto. The anteroposterior transverse and craniocaudal diameters were measured from axial, coronal and sagittal reformatted images. All measurements were taken between the widest points on the sinuses and the volume of each sinus was determined by the product of these three diameters and the slice thickness. On the right, mean sinus volume for males was 14.98cm³, and 13.26cm³ for females. On the left, average sinus volume for males was 15.08cm³, and 16.06cm³ for females. There was a considerable decrease in the mean volume on both sinuses from 14.15cm³ to 13.51cm³ and from 14.33cm³ to 9.61cm³ respectively in relation to increase in age. The overall mean of the right and left maxillary sinus volume were 14.30cm³ and 14.54cm³ respectively. It is therefore concluded that Computerized Tomography measurements may be useful in volume assessment of the maxillary sinus as a preoperative work-up procedure for sinus surgery.

Keywords: Maxillary Sinus, Volume Analysis, Computed Tomography, Sokoto, Nigeria.

INTRODUCTION

The maxillary sinus is the largest of the paranasal sinuses and represents a complex anatomical structure with a significant inter-individual variation (Helmy, Tadros and Micheal, 1969; Sinnatamby, 2005; Koji, Endo and Shimooka, 2009; Uthman, Al-Rawi, Al-Naaimi and Al-Timimi, 2011). The extent of pneumatisation of the maxillary sinus varies from person to person; its volume is influenced by age, residual dental

projections, and alveolar bone height (Woo and Le, 2004; Arijji Y., Arijji E., Yoshiura and Kanda, 1996; Deeb *et al.*, 2011). The normal volume of the maxillary sinus is useful in treatment planning, evaluation of outcome and establishment of base line data (Mehmet *et al.*, (2007). A detailed knowledge of the anatomy of the sinuses is crucial in performing surgical procedures such as functional endoscopic sinus surgery (Mehmet *et al.*, 2007; Maryam *et al.*, 2010). Genetic diseases, environmental conditions and past infections may affect the developmental process and the resultant volume of the maxillary sinus (Karakas and Kavaklý, 2005). Computed Tomography is valuable, simple, fast and painless, now a widely available imaging modality for three-dimensional evaluation of anatomical structures producing thin and multislice CT technology, voxel sizes with submillimeter resolutions, multiplaner and volumetric reconstruction with improved patients comfort, however, its major drawback remains the inherent costs and the radiation concerns (Reichs, 1993; Damman *et al.*, 2000; Maryam *et al.*, 2010).

High resolution CT of the maxillary sinus has become indispensable in the complete evaluation of the maxillary sinus and its lesions (Damman, Bode, Heuschmid *et al.*, 2000), an essential aid in navigation during functional endoscopic sinus surgery (FESS) (Sahlstrand, Magnus, Anita and Kasim, 2011), and a mandatory procedure in the preoperative work-up for sinus surgeries to establish optimal volume of implants (Gray *et al.*, 2000), sinus floor elevation in placement of implants (Kuhl *et al.*, 2010) and to determine the percentage of pneumatization in the sinus cavity (Park *et al.*, 2011).

The volume of the paranasal sinuses tends to decrease with increasing age and the maxillary sinus volume has been found to decrease after the age of 20 years (Jovanic, Jelacic and Kargovska-Klýsarova, 1984). According to Deeb *et al.*, (2011), a reduction in sinus volume in the presence of chronic rhinosinusitis is associated with the increase in cortical bone and mucosal thickness. Other studies have suggested that the maxillary sinus volume increases with age (Arijji *et al.*, 1994; from Kyushu University, Fukuoka, Japan, Sacide and Ahmet, 2005, from Firat University of Medicine, Elazig, Turkey) and loss of teeth (Uemura, 1974, from Japan). The mean volume of the maxillary sinus was 14.75cm³, 20.05cm³, and 14.71cm³ respectively according to Calhoun *et al.*, (1988), from the University of Texas, United State, Amedee, (1993), from Johannes Gutenberg University Mainz, Germany, and Arijji *et al.*, (1994), from Kyushu University, Fukuoka, Japan.

According to Uchida, Goto, Katsuki and Akiyoshi (1998), from Saga Medical School, Nabeshima, Japan, and Kim *et al.*, (2002), from Yonsei University, Seoul, Korea, the average volume of the maxillary sinus is 11.3cm³, and 15.1cm³ respectively. Mean sinus volume in males was 24.04cm³ and 15.85cm³ in females according to Jun *et al.*, (2005), from Catholic University of Korea, Seoul, while Koppe *et al.*, 2006, report from Okayama University School of Dentistry, Japan, that, the right sinus volume was larger than the left, and that asymmetry in maxillary

sinus volume was not related to gender or size of skull. Mehmet *et al.*, (2007), reported from the Department of Anatomy, Medical School, Ondokuz Mayıs University, Samsun, Turkey, that sinus volume was 35.9cm³, while it ranged between 11.1cm³ and 23.0cm³ among Germans at the University of Bonn, Germany (Pirner *et al.*, 2009). Sahlstrand, Magnus, Anita and Kasim (2011), from Lund University and Skane University Teaching Hospital, Malmo., Sweden, report a mean sinus volume of 15.7cm³, while Amusa *et al.*, (2011), report from Obafemi Awolowo University Teaching Hospital, Ile Ife, that the average volume on the right was 11.59cm³ and 14.98cm³ on the left. There is paucity of data on the volume of the maxillary sinus among Nigerians and most of these works were done on Caucasian subjects. The aim of this study is therefore meant to compliment these findings and to establish a baseline data for values in our environment.

MATERIALS AND METHOD

One hundred and thirty subjects comprising 79 males and 51 females, between 20 - 80 years, with normal maxillary sinus CT anatomy, from head CT scans carried out at the Radiology Department of the Usmanu Danfodiyo University Teaching Hospital (UDUTH) Sokoto, over a five year period were recruited for this study. Head CT Scans were obtained from the local data base of the CT machine and back up compact disc from the CT library. Films were viewed on the computer monitor. Good positioning of images was observed to ensure symmetry or asymmetry of the maxillary sinus. Measurements were made with Neusoft Dual Slide Helical CT machine (2005 model, 15cm FOV, 200mA, 120kV, scanning at high resolution bone algorithm at 1 second and slice thickness of 5mm), with software that provides a meter rule, with which linear measurements (craniocaudal, anteroposterior and transverse diameters) in millimeters between the widest points on the sinuses were taken from axial, coronal and sagittal reformatted images. The volume of each sinus was determined by the product of the previous three dimensions and the slice thickness as described by Sahlstrand, Magnus, Anita and Kasim (2011). These measurements were performed on three-dimensional reconstructed images using V-works 3.0 program. Data was manually sorted out, tabulated, entered into computer using Microsoft word and Microsoft Excel and analyzed using Minitab 16.0 statistical package. The mean (\pm SD) volumes were determined and comparisons of mean values were done using Students' t-test.

RESULTS AND DISCUSSION

On the right maxillary sinus, the widest range of volume was recorded between 70 and 79 years, while on the left, the lowest and highest volumes were recorded over 50 – 59 years and 70 – 79 years respectively. However the maximum right sinus mean volume was found in subjects between 30 to 39 years, while it was 15.67cm³ between 70 – 79 years on the left. On the right maxillary sinus, mean volume for males was 14.98cm³ while in females it was 13.26cm³, indicating that there was no

statistically significant difference in the right maxillary sinus volume between males and females. On the left maxillary sinus, the average volume for males was 15.08cm^3 , while for females it was 16.06cm^3 . This showed no statistically significant difference between both sexes. The maxillary sinus volume was found to decrease after the age of 20 years. Although there was no consistent decrease in the sinus volumes as the age increased (table 2), volume decrease with increased age of subjects was established on both right and left maxillary sinus from 14.15cm^3 to 13.51cm^3 and from 14.33cm^3 to 9.61cm^3 respectively in relation to the two extremes of the age groups studied (20 – 29 years and 80 – 89 years). The overall mean of the right and left maxillary sinus volume were 14.30cm^3 and 14.54cm^3 respectively.

In this study, maxillary sinus volume decreased with age and was found to decrease after the age of 20 years as reported by Ariji *et al.*, (1994) from Fukuoka, Japan, Ariji *et al.*, (1996) from Nagasaki, Japan, and from Ondokuz Mayıs University, Samsun, Turkey, by Mehmet *et al.*, (2007). However, from Firat University of Medicine, Elazig, Turkey, Sacide and Ahmet (2005) have it that the maxillary sinus volume increases with age. Our studies found larger volumes on the left maxillary sinus in both sexes; this is *in tandem* with the findings of Nowak and Mehls (1977), from East Germany, and also supported by the report of Amusa *et al.*, (2011), (right: $11.59 \pm 5.36 \text{ cm}^3$ and left: $14.98 \pm 10.77 \text{ cm}^3$), who worked on Nigerians in the south west region, that the left maxillary sinus volume was larger than the right in both males and females. However, Koppe *et al.*, (2006), from Okayama, Japan, maintained that, the volume of the right maxillary sinus was larger than that of the left side.

This study also reveals that no statistically significant difference existed between the right and left maxillary sinus volume of both sexes ($p < 0.001$). With slightly lower volumes except in female left sinus, this results compared favourably with the conclusion from Lund, Sweden, by Sahlstrand *et al.* (2011), who report that no statistically significant difference existed between the left and right maxillary sinus volumes; for males, (right = $18.0\text{cm}^3 \pm 6.00\text{cm}^3$, left = $18.0\text{cm}^3 \pm 7.00\text{cm}^3$) and females (right = $14.0\text{cm}^3 \pm 3.00\text{cm}^3$, left = $15.0\text{cm}^3 \pm 4.00\text{cm}^3$). The average right maxillary sinus volume from this study were higher than the values reported by Amusa *et al.* (2011), (the right was $11.59\text{cm}^3 \pm 5.36\text{cm}^3$ and $14.98\text{cm}^3 \pm 10.77\text{cm}^3$ on the left). Our study also discovers that Nigerians in the North West had larger maxillary sinus volumes compared to Indians in Mysore according to Vidya *et al.* (2013) who reported that sinus volume among Indian males was $13.606\text{cm}^3 \pm 5.247\text{cm}^3$ on the right, and $13.50\text{cm}^3 \pm 6.513\text{cm}^3$ on the left, while in females, it was $9.733\text{cm}^3 \pm 3.389\text{cm}^3$ and $10.908\text{cm}^3 \pm 3.39\text{cm}^3$ for the right and left sinus respectively. However, the values from this study fell within the range of values established by Ariji *et al.* (1994); 4.56cm^3 to 35.2cm^3 (mean = $14.71\text{cm}^3 \pm 6.33\text{cm}^3$) in patients aged over 20 years among Japanese in Fukuoka, and Pirner *et al.*, (2009); $11.1\text{cm}^3 \pm 4.5\text{cm}^3$ to $23.0\text{cm}^3 \pm 6.7\text{cm}^3$ from the University of Bonn,

Germany. The results of this study compared favourably with the reports from the University of Texas, United States by Calhoun *et al.* (1991), Amedee (1993), who reported from Johannes Gutenberg University Mainz, Germany, that the mean volume of the maxillary sinus as 14.75cm³ and 20.05cm³ ± 9.2cm³ respectively, but were lower than the mean maxillary sinus volume in early adults of 24.04cm³ (males) and 15.86cm³ (females) among Koreans in Seoul, by Jun *et al.* (2005).

CONCLUSION

The aim of the study is to determine volume of the maxillary sinus using computed tomography, to correlate this with size, age and sex and to provide baseline data for values in our environment. The results compare favourably with the reports from the University of Texas, United States and Johannes Gutenberg University Mainz, Germany, but were lower than the mean maxillary sinus volume in early adults among Koreans. It therefore concludes that computerized tomography measurements may be useful in volumetric assessment of the maxillary sinus. Sinus volumes decreased with increasing age, and were larger on the left maxillary sinus in both sexes.

Table 1: Mean and Standard Deviation (±SD) of Measurements of the Maxillary Sinus in Relation to Sex Distribution of Subjects Used in the Study

Maxillary sinus Dimensions		Males	Females	t	df	p Value
		Mean (+/- SD)	Mean (+/- SD)			
Right Maxillary Sinus	CC	32.21mm(±5.56)	30.93mm(±6.09)	1.21	100	0.24
	TR	24.18mm(±5.80)	23.14mm(±4.70)	1.12	121	0.27
	AP	36.94mm(±4.73)	36.29mm(±4.71)	0.76	107	0.45
	VOL	14.98cm ³ (±6.53)	13.26 cm ³ (±5.04)	1.68	124	0.09
Left Maxillary Sinus	CC	32.38mm(±5.33)	31.14mm(±6.00)	1.20	98	0.23
	TR	24.12mm(±5.81)	23.69mm(±5.50)	0.43	111	0.67
	AP	36.84mm(±5.31)	36.43mm(±4.64)	0.46	117	0.65
	VOL	15.08cm ³ (±6.66)	16.06cm ³ (±17.96)	- 0.38	59	0.71

CC = Craniocaudal, TR = Transverse, AP = Anteroposterior, VOL= Volume.

Source: Radiology Department of the Usmanu Danfodiyo University Teaching Hospital, Sokoto, 2007-2012

Table 2: Mean and Standard Deviation of the Right and Left Maxillary Sinus Volumes in Relation to Age Groups

Age Groups (Years)	Right Maxillary Sinus		Left Maxillary Sinus	
	Range of Volume (cm ³)	Mean Volume (cm ³)(±SD)	Range of Volume(cm ³)	Mean Volume (cm ³)(±SD)
20–29	4.94–28.35	14.15 (±6.28)	6.27–29.08	14.33 (±5.73)
30–39	6.31–29.62	15.07 (±5.88)	6.35–31.20	15.61 (±6.67)
40–49	6.29–30.90	14.40 (±6.17)	5.96–26.30	13.80 (±6.26)
50–59	5.71–29.04	13.34 (±5.40)	4.16–23.93	14.17 (±5.87)
60–69	7.01–24.10	14.44 (±5.01)	7.26–33.65	14.51 (±6.57)
70–79	4.71–38.57	14.94 (±9.17)	5.00–35.66	15.67 (±8.17)
80–89	12.53–14.50	13.51 (±1.39)	8.04–11.18	9.61 (±2.22)
Overall	4.71–38.57	14.30 (±6.03)	4.16–35.66	14.54 (±6.26)

Source: Radiology Department of the Usmanu Danfodiyo University Teaching Hospital, Sokoto, 2007-2012

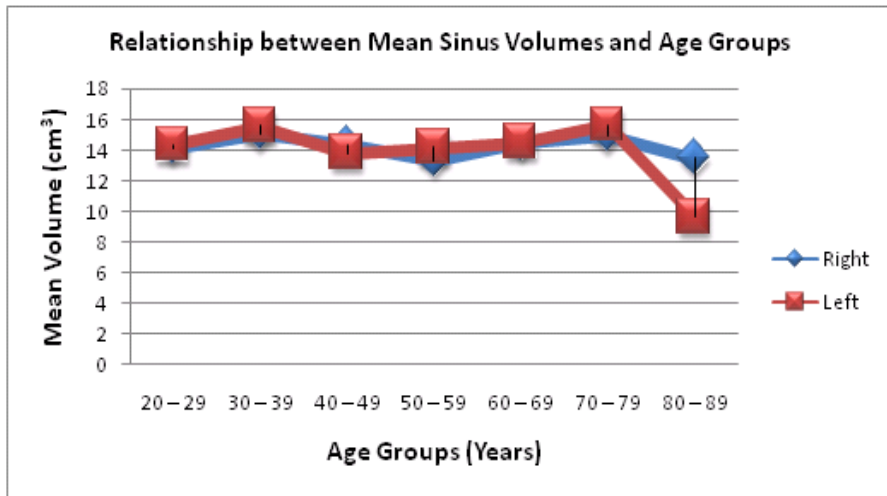


Figure 1: The Relationship Between the Mean Volumes of Both Maxillary Sinuses and the Age Groups.
Source: Radiology Department of the Usmanu Danfodiyo University Teaching Hospital, Sokoto, 2007-2012

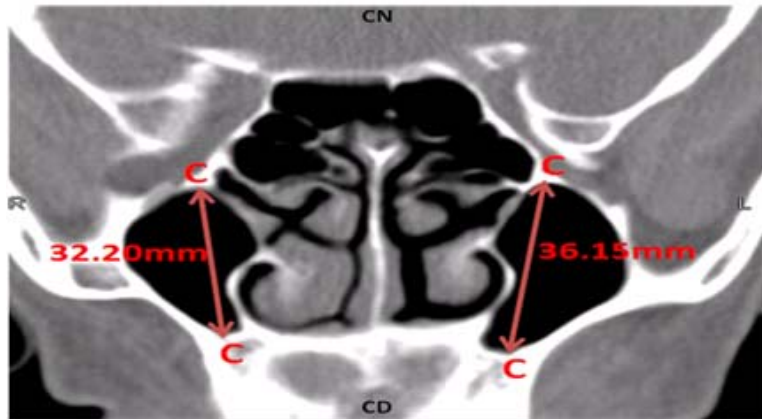


Figure 2: Coronal CT of a 30 year Old Female Showing Measurements of the Craniocaudal (Height) Diameter CC. The Right CC was 32.20mm while the Left CC was 36.15mm. R= Right side, L= Left side, CN= Cranial end, CD= Caudal end.
Source: Radiology Department, Usmanu Danfodiyo University Teaching Hospital, Sokoto, 2007-2012

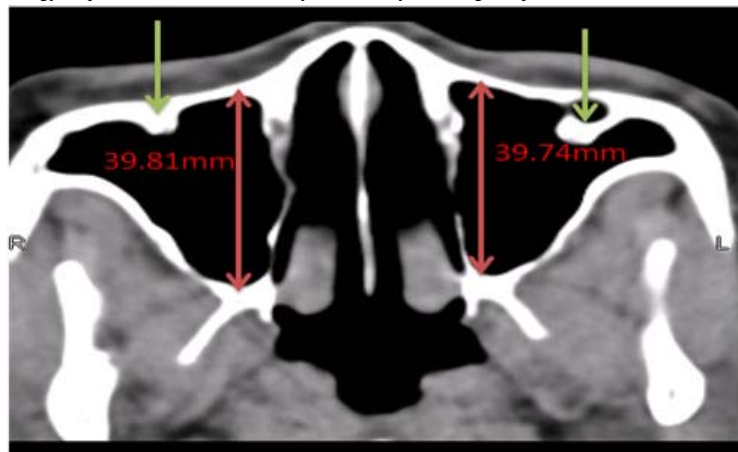

Figure 3: Axial CT of a 45 year of Male Showing Measurement of the Anteroposterior (Depth) Diameter (AP). The Right and Left AP Diameters were 39.81mm and 39.74mm respectively. The Arrows Point towards Septa on the Anterolateral Sinus Wall. R= Right side, L= Left side
Source: Radiology Department of the Usmanu Danfodiyo University Teaching Hospital, Sokoto, 2007-2012

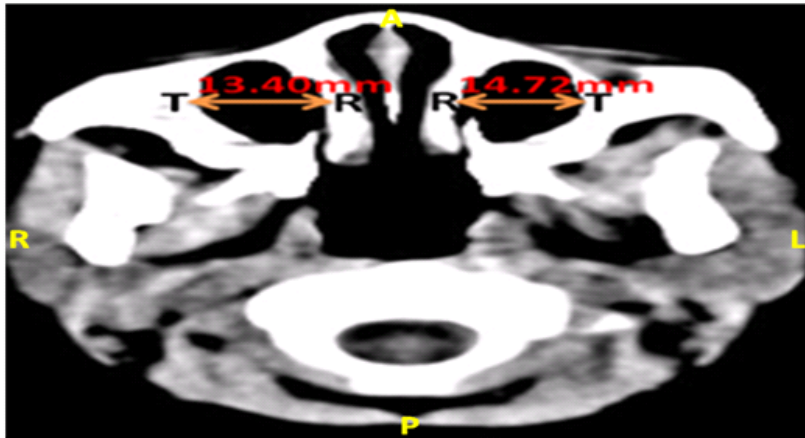


Figure 4: Axial CT of a 27 year Old Female Showing Measurements of the Transverse Diameter (TR). The Right TR is 13.40mm, while TR on the Left is 14.72mm. R= Right side, L= Left side, A= Anterior, P= Posterior.

Source: Radiology Department of the Usmanu Danfodiyo University Teaching Hospital, Sokoto, 2007-2012

REFERENCES

- Amedee R.** (1993): *Sinus Anatomy and Function*. In Barly B. J. (ed). *Head and Neck Surgery. Otolaryngology* (Vol 1). (342-349). Philadelphia: JB Lippincott Company.
- Amusa Y. B., Eziyi J. A. E., Akinlade O., Famurewa O. C., Adewole S. A., Nwoha P. U. and Ameye S. A.** (2011): Volumetric Measurements and Anatomical Variants of Paranasal Sinuses of Africans (Nigerians) Using Dry Crania. *International Journal of Medicine and Medical Science*, 3(10), 299-303.
- Ariji Y., Ariji E., Yoshiura K. and Kanda S.** (1996). Computed Tomographic Indices for Maxillary Sinus Size in Comparison with the Sinus Volume. *Dentomaxillofac Radiology*, 25(1); 19-24.
- Ariji Y., Kuroki T., Moriguchi S., Ariji E., Kanda S.** (1994). Age Changes in the Volume of the Human Maxillary Sinus: A Study Using Computed Tomography. *Dentomaxillofac Radiology* 23(3), 163-8.
- Calhoun K. H., Waggenspack G. A., Simpson C. B., Hokanson J. A., Bailey B. J.** (1991). CT Evaluation of the Paranasal Sinuses in Symptomatic and Asymptomatic Populations. *Otolaryngol Head Neck Surgery*, 104, 480-3.
- Damman, F., Bode A., Heuschmid M. et al.** (2000). Multislice CT of the Paranasal Sinuses: First Experiences Using Parameters of Radiation Dosage. *Rofo*. 172(8), 701-702.
- Deeb R., Malani P. N., Gil B., Jafari-Khouzani K., Soltanian-Zadeh H., Patel S., Zacharek M. A.** (2011). Three-dimensional volumetric measurements and analysis of the maxillary sinus. *American Journal of Rhinology Allergy*, 25, 152-6.
- Gray, C. F., Staff, R. T., Redpath, T. W., Needham, G. and Renny, N. M.** (2000). Assessment of maxillary sinus volume for the sinus lift operation by three-dimensional magnetic resonance imaging. *Dentomaxillofac. Radiology*, 29, 154-8.
- Helmy, I. D., Tadros, A. A. and Micheal, M. A.** (1969). *The Anatomical Basis of Medical Practice. The Human Skeleton* (1st Edition).
- Jovanic S., Jelcic N. and Kargovska-Klȳsarova A.** (1984). Post Natal Development and Relationships of the Maxillary Sinus. *Acta Anatomy*, 118, 122–128.

- Jun B. C., Song S. W., Park C. S., Lee D. H., Cho K. J. and Cho J. H.** (2005). The Analysis of Maxillary Sinus Aeration According to Aging Process; Volume Assessment by 3-Dimensional Reconstruction by High-Resolutional CT Scanning. *Otolaryngol Head Neck Surgery*, 132(3), 429-34.
- Karakas S. and Kavaklý A.** (2005): Morphometric examination of the paranasal sinuses and mastoid air cells using computed tomography. *Annals of Saudi Medicine*, 25(1), 41-45.
- Kim H. J., Yoon H. R., Kim K. D., Kang M. K., Kwak H. H., Park H. D., et al.** (2002), Personal Computer Based Three Dimensional Reconstruction and Simulation of Maxillary Sinus. *Surg Radiol Anatomy*, 24, 393-399.
- Koji K., Endo T. and Shimooka S.** (2009). Effects of Maxillary Second Molar Extraction on Dentofacial Morphology Before and after Anterior Open-bite Treatment: A Cephalometric Study. *Odontology the Society of the Nippon Dental University*, 97(1), 43-50.
- Koppe T., Weigel C., Bärenklau M., Kaduk W., Bayerlein T., Gedrange T.** (2006). Maxillary Sinus Pneumatization of an Adult Skull with an Untreated Bilateral Cleft Palate. *Journal of Craniomaxillofac Surgery*, 34(2), 91-5.
- Kuhl, S., Gotz, H., Hansen, T., Kreisler, M., Behneke, A., Heil, U., Duschner, H., d'Hoedt, B.** (2010). Three-dimensional analysis of bone formation after maxillary sinus augmentation by means of microcomputed tomography: a pilot study. *International Journal of Oral Maxillofacial Implants*, 25, 930-938.
- Maryam, S., Xue, D., Hu, Y., Cleynenbreuge, J., Jacobs, R.** (2010). Spiral Computed Tomography Based Maxillary Sinus Imaging in Relation to Tooth Loss, Implant Placement and Potential Grafting Procedure. *Journal of Oral and Maxillofacial Research*, 1(1), e7.
- Mehmet, E., Sahin, B., Bilgic, S., Celebi, M., Uzun, A.** (2007). Volumetric Evaluation of the Paranasal Sinuses in Normal Subjects Using Computer Tomography Images: a Stereological Study. *Auris Nasus Larynx*, 34, 191-195.
- Nowak R. and Mehls G.** (1977). X-ray Films Analysis of the Sinus Paranasales from Cleft Patients (In Comparism with a Healthy Group). *Anatomy Anz.* 142 (5), 451-470.
- Park, Y. B., Jeon, H. S., Shim, J. S., Lee, K. W., Moon, H. S.** (2011). Analysis of the anatomy of the maxillary sinus septum using 3-dimensional computed tomography. *Journal of Oral Maxillofacial Surgery*, 69, 1070-1078.
- Pirner S., Tingelhoff K., Wagner I., Westphal R., Rilk M., Wahl F. M., Bootz F. and Eichhorn K. W.** (2009). CT-Based Manual Segmentation and Evaluation of Paranasal Sinuses. *European Arch Otorhinolaryngology*, 266(4), 507-518.
- Reichs K. J.** (1993). Quantified Comparison of Frontal Sinus Patterns by Means of Computed Tomography. *Forensic Science International*, 61, 141-168.
- Sacide, K. and Ahmet, K.** (2005). Morphometric Examination of the Paranasal Sinuses and Mastoid Air Cells Using Computed Tomography. *Annals of Saudi Medicine*, 25 (1), 41-45.
- Sahlstrand J. P., Magnus J., Anita S. and Kasim A.** (2011). Computed tomography measurements of different dimensions of maxillary and frontal sinuses. *BMC Medical Imaging*, 11, 8-11.
- Sinnatamby, C. S.** (ed). (2005). *Last's Anatomy. Regional and Applied* (11th ed.), Churchill Livingstone: Edinburgh.
- Uchida, Y., Goto, M., Katsuki, T. and Akiyoshi, T.** (1998). A Cadaveric Study of Maxillary Sinus Size as an Aid in Bone Grafting of the Maxillary Sinus Floor. *Journal of Oral Maxillofacial Surgery*, 56(10), 1158-1163.

- Uemura J.** (1974). Morphological Studies on the Maxilla of the Edentulous Skulls and the Skulls with Teeth. *Shikwa Gakuho*. 74(12), 1860-1889.
- Uthman N., Al-Rawi A., Al-Naaimi J. and Al-Timimi** (2011). Evaluation of Maxillary Sinus Dimensions in Gender Determination Using Helical CT Scanning. *Journal of Forensic Sciences*, 56, 403- 408.
- Vidya C. S., Shamasundar N. M., Manjunatha B. and Keshav B.** (2013). Evaluation of the Size and Volume of the Maxillary Sinuse to Determine Gender by 3D Computerized Tomography Scan Method Using Dry Skulls of South Indian Origin. *International Journal of Cur Res Rev*. 5(3), 97 – 100.
- Woo, I. and Le, B. T.** (2004). Maxillary Sinus Floor Elevation; Review of Anatomy and Two Techniques: Implant Dentistry. Lippincott: Williams & Wilkins.