

Measurements of Foramen Magnum Using Computerised Tomography in Sokoto State, Nigeria

*¹Bello S. S., ¹Zagga A. D., ²Kalale S. B., ¹Usman J. D., ¹Bello A.,
¹Abdulhameed A., ¹Bello S. M., and ¹Tadros A. A.

Departments of ¹Anatomy and ²Radiology
College of Health Sciences,
Usmanu Danfodiyo University, Sokoto, Nigeria
*E-mail: ssbello2009@hotmail.com

ABSTRACT

This study, Measurements of Foramen Magnum Using Computerised Tomography in Sokoto State, Nigeria was aimed at assessing the anteroposterior diameter and width of the foramen magnum, the anteroposterior diameter and width of the occipital condyles as well as the bicondylar distance taken from normal cranial CT scans of subjects with the aim of determining the sex of the subjects as was previously employed by Selma-Uysal, et al 2005 in Turkish population. Cranial CT Scans were obtained from the local data base of the CT machine and back up compact disc from the CT library. Films were viewed on the computer monitor. Measurement was made with Dragon V3.1.1 Philips and Neusoft Medical System Company Limited software, the software provides a meter rule with which measurements were done. A total of 240 subjects were involved in the study, out of which, 73.75% were males. The ratio of male to female was 2.8:1. The age range of the subjects used in this study was 20 to 79 years. The range of the foramen magnum diameters were 22.3mm to 45.9mm for anterior posterior diameter and 19.9mm to 38.3mm for the width of the foramen magnum. The mean anterior posterior diameter and width of the foramen magnum were 34.3mm and 30.1mm respectively. This study reports that the dimensions of the foramen magnum are greater in Nigerian males than in their female counterparts and are statistically significant for width of the foramen magnum. The increase in age of individuals after the age of 20 years will not affect the foramen magnum diameters.

Keywords: Foramen magnum, measurement, CT, Sokoto, Nigeria.

INTRODUCTION

Foramen magnum evaluations are very important not only to establish the most proper operational techniques, but also to obtain useful data for unknown sex determination and identity in forensic medicine (Bozbuga *et al.*, 1999). Studies related to morphometric analysis of Antero-Posterior Diameter (APD) and Transverse Diameter (TD) of the foramen magnum showed differences and has an extreme importance in sex determination (Lang, Schafhauser and Hoffmann, 1983; Sindel, Özkan, Uçar and Demir, 1989; Çalgüner, 1991). The sagittal and transverse dimensions of the foramen magnum are significantly higher in men's skulls. The mean sagittal diameters were 36.5mm and 35.6mm for male and female respectively

and the mean transverse diameters were 30.6mm and 29.5mm for male and female respectively (Catalina-Hercera, 1987). Lang and Hornung (1993), in a study in Germany on comparison of the difference between the transverse diameter and anteroposterior diameter values of foramen magnum in male and female subjects showed statistical significance in terms of size. The study showed that in male subjects, the anteroposterior diameter and transverse diameter values were larger than those found in females, the anteroposterior diameter of foramen magnum was found to be 35.33mm, and the transverse diameter 29.67mm.

The anteroposterior diameters of the foramen magnum were on average significantly greater than transverse diameters, this is consistent with the normal oval shape of the foramen magnum. Furthermore, both diameters show an inter-individual variability and both are normally distributed (Philipp, Maciej, Thomas and Frank, 2009). In this study on central european male and female dry skulls, the anteroposterior diameter ranges from the minimum value of 30mm to maximum value of 43mm. The transverse diameter ranges from the minimum value of 25 mm to the maximum of 39 mm (Philipp, Maciej, Thomas and Frank, 2009). The diameters of the female foramen magnum are on average slightly smaller than those of the males (Philipp, Maciej, Thomas and Frank, 2009). It was found that a weak positive correlation with individual age exists for both diameters (anteroposterior diameter: $r = 0.22$, transverse diameter: $r = 0.10$), yet none is significant. Fatma, Vedat, Mehmet and Oktay, 2010, in the study that was carried out on 95 adult dry skulls in Sivas Turkey, the mean anteroposterior diameter of the foramen magnum was found to be $3.63\text{cm} \pm 0.27\text{cm}$, and the transverse diameter $3.04\text{cm} \pm 0.27\text{cm}$. On the other hand, CT measurements of 23 outpatients reveals that mean of anteroposterior diameter value was $36.4\text{mm} \pm 2.8\text{mm}$, and that the mean of transverse diameter value was $30.0\text{mm} \pm 1.4\text{mm}$ (Fatma, Vedat, Mehmet and Oktay, 2010). The main objective of this study is to evaluate the foramen magnum in sex determination using computerize tomography scan. And to compare and contrast the respective measurements of the foramen magnum between sexes and between various age groups.

MATERIALS AND METHOD

All available Cranial CT scans of subjects done in the Radiology Department of the Usmanu Danfodiyo University Teaching Hospital (UDUTH) Sokoto, from 2008 - 2012, which were reported as normal by a consultant Radiologist, with 3 years experience, were recruited for the study. Computerized tomographic scan for the study were selected based on Inclusion Criteria and Exclusion Criteria.

Inclusion Criteria

- (a) Good positioning of the patient. With the Passage of the lowest tomographic section through a line 15-20 degrees to and 1cm above the cantho-meatal line which represents the base of the skull.
- (b) Distinctly shown foramen magnum and occipital condyles with clear margins.

Exclusion Criteria:

- (a) All cranial computerized tomographic scans showing morphological changes affecting the normal anatomy of the foramen magnum, 22 were excluded.
- (b) All films that showed alteration of the size, shape or asymmetry of the foramen magnum, 15 were excluded.
- (c) All cranial computerized tomographic scans with poor positioning of the patients, 5 were excluded.
- (d) All cranial computerized tomographic scans with poor quality of the scan images 7 were excluded.
- (e) All cranial computerized tomographic scans that were not interpreted by the Radiologist 33 were excluded.

The total number of Cranial CT scans done in the department during the study period was 1,342 out of which, 322 scans were reported to have normal foramen magnum and occipital condyles. However, only 240 CT scans satisfied the inclusion criteria. Equipment used in taking the Crainal CT Scans used in the study include NEUSOFT C 3000 Spiral CT machine Dual Slide Helical CT (2005) model. Cranial computerized tomographic Scans were obtained from the local data base of the computerized tomographic machine and back up compact disc from the computerized tomographic library. Films were viewed on the computer monitor. Good positioning to determine symmetry or asymmetry was ascertained. Presence or absence of pathology was also noted. Measurement was made with Dragon V3.1.1 Philips and Neusoft Medical System Company Limited software, the software provides a meter rule with which measurements will be done, based on the method adapted by (Selma-Uysal *et al.*, 2005). Data were initially sorted out, tabulated and then entered into computer using Microsoft word and Microsoft Excel manually. Minitab 16.0 statistical package was used for data analysis. The mean lengths and widths of foramen magnum and occipital condyles were determined.

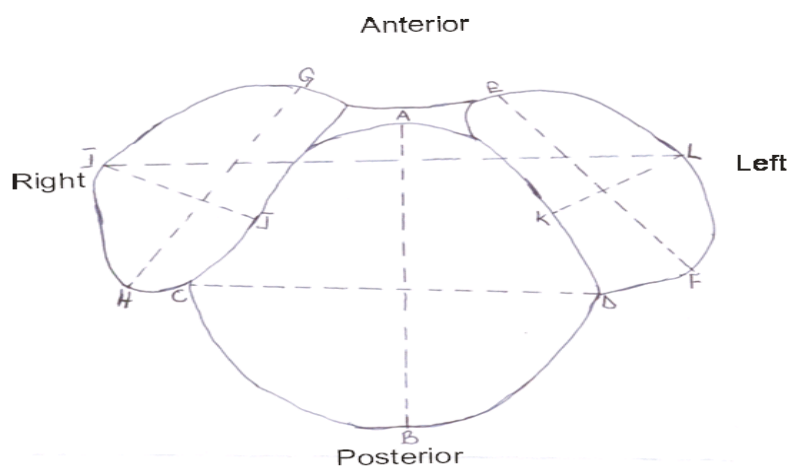


Fig 1: An Annotated Diagram of Foramen Magnum and Occipital Condyles Showing Landmarks of Measurement.

A	=	Summit of anterior border of the foramen magnum.
B	=	Summit of posterior border of the foramen magnum.
C	=	Point at which the lower part of right condyle meets the lateral boundary of foramen magnum.
D	=	Point at which the lower part of left condyle meets the lateral boundary of foramen magnum.
E	=	middle of the anterior border of the left condyle.
F	=	middle of the posterior border of the left condyle.
G	=	middle of the anterior border of the right condyle.
H	=	middle of the posterior border of the right condyle.
I	=	middle of the lateral border of the right condyle.
J	=	middle of the medial border of the right condyle.
K	=	middle of the medial border of the left condyle.
L	=	middle of the lateral border of the left condyle.

The following diameters were measured (Fig 1).

1. G-H (Length of the right occipital condyle): The maximum length of condyle along the long axis from the edges of the articular surface.
2. I-J (Width of the right occipital condyle): The maximum width of condyle from the articular edges along a line perpendicular to the long axis.
3. E-F (Length of the left occipital condyle): The maximum length of condyle along the long axis from the edges of the articular surface.
4. K-L (Width of the left occipital condyle): The maximum width of condyle from the articular edges along a line perpendicular to the long axis.
5. I-L (Maximum bicondylar distance): The bicondylar breadth; the maximum distance between the lateral edges of the articular surfaces of the condyles.
6. A-B (Length of the foramen magnum): The maximum internal length of the foramen magnum along the midsagittal plane.
7. C-D (Width of the foramen magnum): The maximum internal width of the foramen magnum perpendicular to the midsagittal plane.

RESULTS AND DISCUSSION

A total of 240 subjects were involved in the study. Out of this number, 26.25% were females and 73.75% were males. The ratio of male to female was 2.8:1. The age range of the subjects used in this study was 20 to 79 years, and the mean age was 42.7 years (± 16.4). The range of the foramen magnum diameters were 22.3mm to 45.9mm for anterior posterior diameter and 19.9mm to 38.3mm for the width of the foramen magnum. The mean anterior posterior diameter and width of the foramen magnum were 34.3mm (± 4.1) and 30.1mm (± 3.1) respectively. Table 2 compares the mean and standard deviation of the foramen magnum diameters, for males and females used in the study. The mean for the anteroposterior diameter in male subjects

was 34.5mm (± 3.9), and that of the female subject 33.5mm (± 4.5). The P value = 0.11428. This indicates that there is no statistically significant difference among the sexes. The mean measurement for the foramen magnum width in male subjects was 30.6mm (± 2.8) and that of the female subjects was 28.9mm (± 3.5). The P value = 0.00075. This indicates that there was statistically significant difference between the sexes. The mean anteroposterior diameter of the foramen magnum of subjects according to the age groups were 33.7mm (± 3.9) for 20-29 years, 34.7mm (± 4.1) for 30-39 years, 34.9mm (± 4.4) for 40-49 years, 34.8mm (± 4.7) 50-59 years, 33.6mm (± 3.1) for 60-69 years and for age group 70-79 years it was 34.5mm (± 4.1). The mean width of the foramen magnum of subjects according to the age groups were 30.3mm (± 3.0) for 20-29 years, 30.4mm (± 3.1) for 30-39 years, 30.4mm (± 3.1) for 40-49 years, 30.2mm (± 3.3) 50-59 years, 29.5mm (± 2.3) for 60-69 years and for age group 70-79 years it was 28.8mm (± 3.7). In this study the mean anterior posterior diameter and the width of the foramen magnum in all subjects were found to be 34.3mm (± 4.1) and 30.1mm (± 3.1) respectively. This is close to what was found by Osunwoke, Oladipo, Gwunireama and Ngaokere (2012) in Anambra State, Nigeria, which were found to be 36.11mm and 29.56mm for the mean length and width of the foramen magnum respectively.

This study finds the mean anterior posterior diameter in male subjects as 34.5mm (± 3.9) and that of the female subjects 33.5mm (± 4.5) with no significance statistically, the mean width of the foramen magnum in male subjects was 30.6mm (± 2.8) and that of the female subjects was 28.9mm (± 3.5) which is statistically significant. This shows a larger value in males than in females, which is the same as reported by Catalina-Herrera (1987) from Spain and Selma-Uysal *et al* (2005) from Turkish population. The mean anteroposterior diameter and width of the foramen magnum in relation to the age groups of subjects studied shows no difference across the age groups from 20 to 79 years of age. The measurements in female age group shows increase in both diameters with increase in age up to the age group of 50-59 and then it starts to decrease with age increment.

Table 1: Mean and Standard Deviation (\pm SD) of the Foramen Magnum Diameters for Subjects Used in the Study

Foramen magnum and occipital condyle diameters	Age range (years)	Range of measurement (mm)	Mean (\pm SD) (mm)
Foramen magnum A-P diameter (mm) n=240	20-79	22.3-45.9	34.3(± 4.1)
Foramen magnum Width (mm) n=240	20-79	19.9-38.3	30.1(± 3.1)

A-P = Anteroposterior

Source: Empirical Observation, 2013

Table 2: Shows the Mean and Standard Deviation (\pm SD) of the Foramen Magnum Diameters in Relation to Sex of the Subjects Used in the Study.

Foramen Magnum diameters	Mean(mm) (\pm SD)	Mean(mm) (\pm SD)	P Value
	Males	Females	
Anteroposterior Diameter	34.5(\pm 3.9)	33.5(\pm 4.5)	0.11428
Width	30.6 (\pm 2.8)	28.9(\pm 3.5)	*0.00075

*statistically significant at P Value > 0.05

Source: Empirical Observation, 2013

Table 3: Shows Mean and Standard Deviation (\pm SD) of the Foramen Magnum Diameters in Relation to Age Group of Subjects Used in the Study

Age (years)	Frequency number of subject in the age group	A-P diameter of the foramen magnum (mm) \pm 1SD	Width of the foramen magnum (mm) \pm 1SD
20-29	70	33.7(\pm 3.9)	30.3(\pm 3.0)
30-39	41	34.7(\pm 4.1)	30.4(\pm 3.1)
40-49	35	34.9(\pm 4.4)	30.4(\pm 3.1)
50-59	42	34.8(\pm 4.7)	30.2(\pm 3.3)
60-69	31	33.6(\pm 3.1)	29.5(\pm 2.3)
70-79	21	34.5(\pm 4.1)	28.8(\pm 3.7)

Source: Empirical Observation, 2013

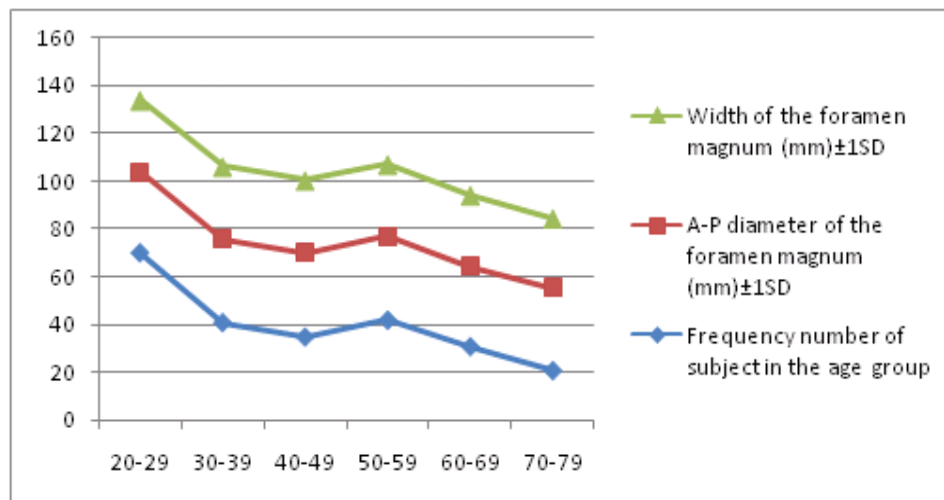


Figure 2: Graphical Representation of the Mean Length and Width of the Foramen Magnum in Relation to Age Group and Frequency of the Subjects Used in the Study.

CONCLUSION

The foramen magnum is a three dimensional aperture within the basal central region of the occipital bone. It is an oval or circular aperture in the base of the skull (Ukoha et al., 2011). It transmits the medulla oblongata and its membranes, the spinal accessory nerve, vertebral arteries, the anterior and posterior spinal arteries, the membrane tectoria and alar ligaments (Ukoha et al., 2011). Studies related to

morphometric analysis of antero-posterior diameter (APD) and transverse diameter (TD) of the foramen magnum showed differences and has an extreme importance in sex determination. The age range of subject used in this study was 20 to 79 years this is fairly comparable with the age range of individuals used by Giles and Eliot (1963) which is between 21 to 75 years. This study concludes that the dimensions of the foramen magnum are greater in Nigerian males than in their female counterparts and are statistically significant for width of the foramen magnum. The increase in age of individuals after the age of 20 years will not affect the foramen magnum diameters.

REFERENCES

- Bozbuga, M., Ozturk, A., Bayraktar, B., Ari, Z., Sahinoglu, K., Polat, G. and Gurel, I.** (1999). Surgical anatomy and morphometric analysis of the occipital condyles and foramen magnum. *Okajimas Folia Anatomy of Japan*, 75, 329-334.
- Çalgüner, E.** (1991). Foramen magnum unanatomik varyasyonlar? v morfometrikde? erlendirmesi. *Gazi T?p Dergisi*, 2, 25-30.
- Catalina-Hercera C. J.** (1987). Study of the Anatomical matrix values of the foramen magnum and its relation to sex. *Acta Anatomy*, 130, 344-347
- Fatma H. E., Vedat S., Mehmet Ç. and Oktay I.** (2010). Morphometric Analysis of the Foramen Magnum by Computed Tomography. *Cilt*, 32(3), 167-170.
- Giles E. and Eliot O.** (1963). Sex determination by discriminant function analysis of crania. *American Journal of Physical Anthropology*, 21, 53-68.
- Lang, J. and Hornung, G.** (1993). The hypoglossal channel and its contents in the posterolateral access to the petroclival area. *Neurochirurgia*, 36, 75-80.
- Lang, J., Schafhauser, O. and Hoffmann, S.** (1983). Postnatal development of transbasal skull openings: carotid canal, jugular foramen, hypoglossal canal, condylar canal and foramen magnum (German). *AnatAnz*, 153(4), 315-357.
- Osunwoke E. A., Oladipo G. S., Gwunireama I. U. and Ngaokere J. O.** (2012). Morphometric analysis of the foramen magnum and jugular foramen in adult skulls in southern Nigerian population. *American Journal of Science and Industrial Research*, 3(6), 446-448.
- Philipp G., Maciej H., Thomas B. and Frank J. R.** (2009). Variability of Human Foramen Magnum Size. *The Anatomical Record: Advances in Integrative Anatomy and Evolutionary Biology*, 292 (11), 1713-1719. Accessed at <http://onlinelibrary.wiley.com/doi/10.1002/ar.v292:11/issuetoc>.
- Selma-Uysal, R. M., Dilek Gokharman, M. D., Mahmut Kacar, M. D., Is?l Tuncbilek, M. D. and Ugur Kosar, M. D.** (2005). Estimation of Sex by 3D CT Measurements of the Foramen Magnum. *Journal of Forensic Science*, 50 (6), 1-5
- Sindel, M., Özkan, O., Uçar, Y. and Demir, S.** (1989). Foramen Magnum 'un Anatomik Varyasyonlar?. *Akdeniz Üniversitesi T?p Fakültesi Dergisi*, 44, 97-102.
- Ukoha U., Egwu O. A., Okafor I. J., Anyabolu A. E., Ndukwe G. U., and Okpala I.** (2011). Sexual Dimorphism in the Foramen Magnum of Nigerian Adult. *International Journal of Biology and Medical Research*, 2(4), 878 - 881